







## Defining Heart Failure Based on Imaging the Heart and Beyond

Fraser J Graham <sup>1</sup>, Antonio Iaconelli <sup>1</sup>, Piotr Sonecki,<sup>2</sup> Ross T Campbell <sup>1</sup>, David Hunter <sup>1</sup>, John GF Cleland <sup>1</sup>  
and Pierpaolo Pellicori <sup>1</sup>

1. School of Cardiovascular and Metabolic Health, University of Glasgow, Glasgow, UK; 2. Queen Elizabeth University Hospital, Glasgow, UK

### Abstract

Water and salt retention, in other words congestion, are fundamental to the pathophysiology of heart failure and are important therapeutic targets. Echocardiography is the key tool with which to assess cardiac structure and function in the initial diagnostic workup of patients with suspected heart failure and is essential for guiding treatment and stratifying risk. Ultrasound can also be used to identify and quantify congestion in the great veins, kidneys and lungs. More advanced imaging methods might further clarify the aetiology of heart failure and its consequences for the heart and periphery, thereby improving the efficiency and quality of care tailored with greater precision to individual patient need.

### Keywords

Congestion, ultrasound, inferior vena cava, jugular vein, heart failure

**Disclosure:** FJG has received financial support from Pharmacosmos for travel to international meetings. RTC has received grants and honoraria from AstraZeneca and has participated in an advisory board for Bayer HealthCare Pharmaceuticals LLC. JGFC has received funding from British Heart Foundation; personal fees from Abbott, Amgen, Novartis, Medtronic, Idorsia, Servier, AstraZeneca, Innolife, Torrent and Respicardia; grants and personal fees from Bayer, Bristol Myers Squibb, Vifor, Johnson & Johnson, Myokardia and Viscardia; personal fees and non-financial support from Boehringer Ingelheim and NI Medical; and grants from Pharma Nord and Pharmacosmos. PP has received consultancy honoraria and/or sponsorship support from Boehringer Ingelheim, Pharmacosmos, Novartis, Vifor, AstraZeneca and Caption Health; and research support from Bristol Myers Squibb. All other authors have no conflicts of interest to declare.

**Acknowledgments:** FJG and AI contributed equally. The current manuscript summarises the content of discussions started by this group in July 2022, during the masterclass 'Relevance and Identification of Congestion in Heart Failure', which was sponsored by Heart Research UK (<https://heartresearch.org.uk/>), a national charity. We thank Dr Jeroen Dauw (Genk, Belgium) for providing images of discontinuous venous renal flow.

**Received:** 26 October 2022 **Accepted:** 19 February 2023 **Citation:** *Cardiac Failure Review* 2023;9:e10. **DOI:** <https://doi.org/10.15420/cfr.2022.29>

**Correspondence:** Pierpaolo Pellicori, School of Cardiovascular and Metabolic Health, University of Glasgow, 126 University Place, Glasgow G12 8TA, UK.  
E: [Pierpaolo.pellicori@glasgow.ac.uk](mailto:Pierpaolo.pellicori@glasgow.ac.uk)

**Open Access:** This work is open access under the CC-BY-NC 4.0 License which allows users to copy, redistribute and make derivative works for non-commercial purposes, provided the original work is cited correctly.

Heart failure is an umbrella term for a variety of common and serious problems that are often overlooked in clinical practice.<sup>1</sup> Two universal definitions of heart failure have recently been proposed; both highlight the central role of congestion in the pathophysiology and presentation of heart failure.<sup>2,3</sup> One definition requires symptoms (such as exertional breathlessness) and clinical signs (such as peripheral oedema) of congestion to make a diagnosis of heart failure.<sup>2</sup> However, symptoms and signs are late manifestations of disease and lack specificity until they are severe. Indeed, for many patients, symptoms and signs of heart failure go unrecognised until they are so severe that admission to hospital is required.<sup>4</sup> Intervening earlier might delay disease progression more effectively.<sup>5,6</sup>

Higher plasma concentrations of natriuretic peptides reflect increases in intra-cardiac pressures and transmural myocardial wall tension due to cardiac dysfunction; they are associated with an adverse prognosis even in the absence of obvious symptoms. However, natriuretic peptides provide little-to-no information on the aetiology of heart failure.

Imaging, particularly by ultrasound, provides information on cardiac structure and function to guide introduction of appropriate treatments,

and can also be used to identify and quantify congestion – both haemodynamic or vascular – and water excess in the tissues of other organs, as we will discuss in this review (*Figure 1*).<sup>7</sup>

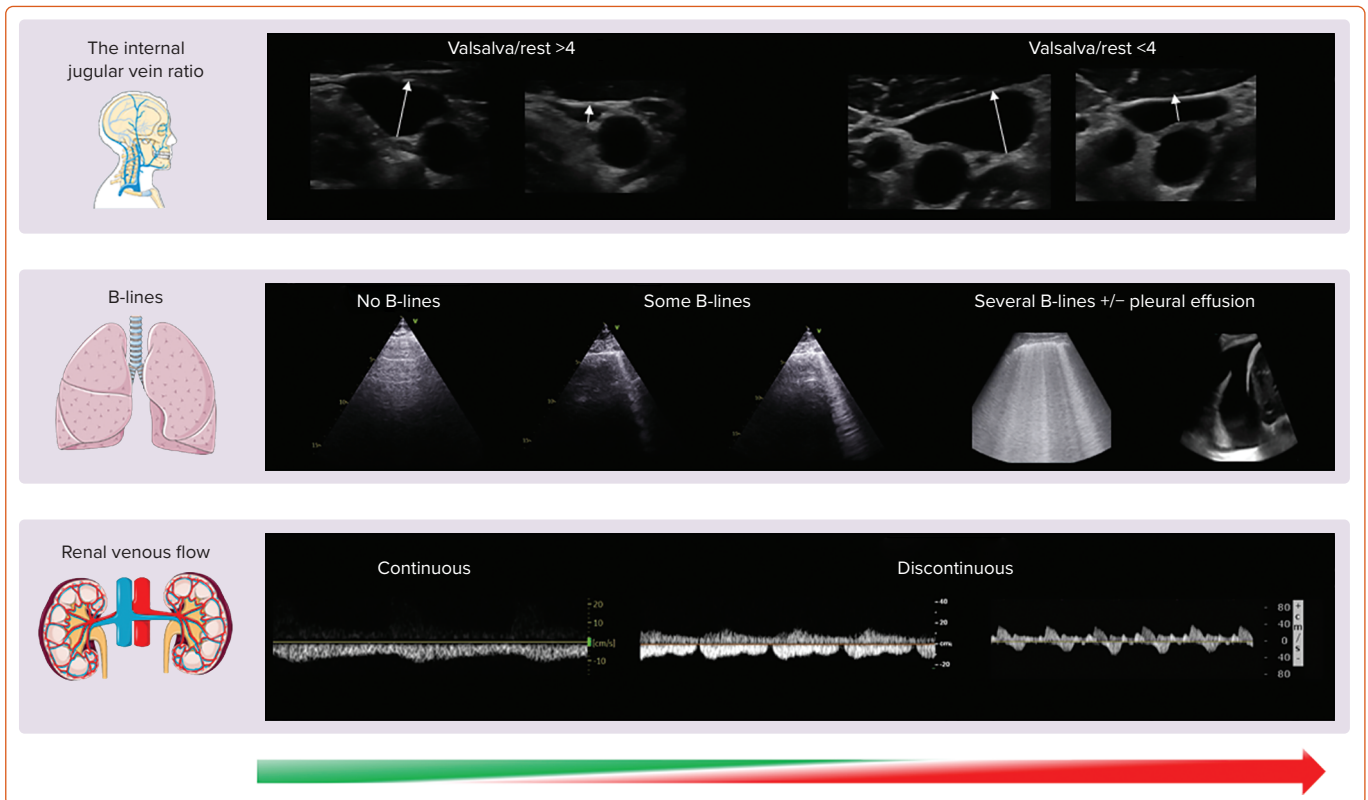
### Echocardiography

Echocardiography is fundamental in the assessment of myocardial structure and function. Through a complex process involving the transmission and subsequent reflection of ultrasound waves, dynamic motion imaging of the heart can be obtained and interpreted in real time via echocardiography. Compared with other complex imaging modalities, echocardiography is widely accessible, free from radiation, relatively affordable and highly versatile; it can provide detailed information on cardiac haemodynamics and valvular function, either at patient's bedside or in the outpatient setting.<sup>8</sup> As a result, it remains the most useful initial imaging diagnostic tool for the vast majority of patients with suspected or diagnosed heart failure.<sup>9</sup>

### The Left Ventricle

The first question that an echocardiographer is asked to answer in a patient with heart failure is usually: "what is the left ventricular ejection fraction?" In its simplest sense, the left ventricular ejection fraction (LVEF) is the percentage of blood that the left ventricle (LV) ejects during systole,

Figure 1: Imaging of Venous, Pulmonary and Renal Congestion by Ultrasound



With increasing severity of congestion (green to red/left to right; bottom arrow), the ratio between the diameter of the jugular vein during Valsalva to that at rest decreases (top panel), the number of B-lines increases and eventually pleural effusion develops (central panel) and the renal venous flow becomes discontinuous (bottom panel); Source: Created using Servier Medical Art. Used with permission under a Creative Commons CC BY licence.

relative to end-diastole. It reflects the systolic contractility of the LV and – although influenced by changes in loading conditions (volume status, blood pressure) and underlying cardiac rhythm (for instance AF) – its accurate assessment is pivotal in determining the heart failure ‘phenotype’. This guides eligibility for medical or device therapies, inclusion in clinical trials and the assessment of recovery of function in optimally treated patients. Assessment of LVEF can be qualitative (subjective) or quantitative (objective). Cardiologists and sonographers should strive towards attainment of objective measures of ejection fraction over subjective ‘eyeball’ measurement; the latter is usually the result of poor echocardiographic windows, suboptimal training or insufficient scan time.<sup>10</sup> Simpson’s biplane method is the day-to-day standard for LVEF measurement. In cases of poor imaging quality, LV contrast agents can be used to opacify the LV, allowing more accurate interpretation of LVEF.<sup>11</sup> Newer methods for assessing LV volumes using 3D applications have improved accuracy compared with cardiac magnetic resonance (CMR) as a gold-standard.<sup>12</sup> The use of 3D echocardiography also aids in the interpretation and quantification of valvular disease, such as mitral regurgitation, which is common in patients with heart failure, but it is reliant on good image quality.<sup>13</sup>

Speckle tracking echocardiography tracks multiple specific regions, or speckles, of the myocardium and can evaluate global or regional longitudinal, circumferential and radial myocardial deformation.<sup>14,15</sup> A worsening (less negative/more positive value) global longitudinal strain (GLS), in particular, correlates with increasing natriuretic peptides and might facilitate identification of those with heart failure and preserved LVEF.<sup>16</sup> GLS can also be useful in the longitudinal follow-up of patients being treated with cardio-toxic agents, to identify those in whom a change

in oncological and/or cardio-protective therapy might be warranted, or in gauging response to therapy for cardiac amyloidosis.<sup>11,17</sup>

### The Left Atrium

Current diagnostic algorithms proposed to identify elevated cardiac filling pressure are time consuming with limited applicability in routine clinical practice. The left atrium (LA) is a thin-walled chamber that acts as a reservoir, conduit and pump for oxygenated blood prior to transport to the muscular, sub-systemic LV. The LA dilates in response to chronic elevations in pressure, which may be due to LV or mitral valve dysfunction or both. A dilated LA is associated with elevated natriuretic peptide levels and with an increased risk of a broad range of cardiovascular events both in patients with heart failure and the general population, particularly AF, a common precipitant of heart failure symptoms and signs.<sup>18–21</sup> Transition from dilation to LA dysfunction and failure might lead to poorer prognosis; treatments that decrease LA size might delay onset of heart failure or progression of disease.<sup>22–25</sup>

### The Right Side of the Heart

The failure to control elevated LV filling pressures eventually leads to right ventricular (RV) dysfunction, development of venous hypertension and poorer prognosis.<sup>26</sup> In clinical practice, pulmonary artery systolic pressure can be estimated from the peak velocity of the tricuspid regurgitant jet via Doppler. When elevated, it identifies patients with heart failure with more severe symptoms and greater risk of death; however, reliability of this method is questionable in the presence of severe tricuspid regurgitation or substantial RV dysfunction.<sup>27</sup> The inferior vena cava (IVC) diameter and its changes with respiratory manoeuvres can be easily assessed in the vast majority of patients with heart failure to estimate fluid status and right

atrial (RA) pressure.<sup>28</sup> Almost 20% of outpatients with heart failure who are clinically free from signs or symptoms of congestion have a dilated IVC; interestingly, a dilated IVC can be also identified in >10% of those with cardiovascular risk factors only, such as diabetes or hypertension.<sup>29,30</sup> An increasing IVC diameter is associated with a larger LA, higher natriuretic peptides and a greater risk of premature cardiovascular events, regardless of LVEF. Conversely, in patients with chronic heart failure, a non-dilated IVC that collapses >50% with inspiration is associated with better prognosis.<sup>31</sup> For those who are hospitalised with heart failure, serial assessment of IVC diameter might be used to monitor response to diuretic therapy; for those in whom the IVC remains dilated at discharge, there is a high risk of an early readmission.<sup>32</sup> On-going clinical trials are evaluating whether treatment guided by changes in IVC diameter improves management of congestion in patients hospitalised with heart failure (NCT04549701 and NCT03140566).

### Jugular Vein Assessment

When assessment of the IVC is difficult, either because not tolerated or limited by the patient's body habitus, RA pressures or intravascular volume can be estimated by ultrasonic evaluation of the internal jugular vein (IJV). The IJV lies in the carotid sheath, close to the carotid artery and is covered – superficially – by the sternocleidomastoid muscle in the neck. Using a high frequency transducer, the IJV can be easily imaged in every person.

With the patient's head and neck reclined at 45–60° degrees, in normal haemodynamic conditions, the IJV is almost collapsed; its distension can be provoked by asking the patient to perform a Valsalva manoeuvre, causing a rapid increase in venous pressures. The ratio between the maximal IJV diameter during Valsalva to that at rest or the percentage of cross-sectional area change correlate with natriuretic peptides and RV function.<sup>33,34</sup> An already distended jugular vein at rest will only marginally increase in size during a Valsalva: in that case, intravascular congestion is likely to be substantial, as is the risk of hospitalisation or death.<sup>35,36</sup>

### Lung Ultrasound

Frank pulmonary oedema may be triggered by an acute event and usually presents as a symptomatic crisis. However, many patients with heart failure have persistent pulmonary congestion that is not clinically or radiologically obvious in routine clinical practice. Ultrasound is a quick and simple test that can be performed in minutes at the bedside to identify de-aerated segments of the lung, the consequence of which will be vertical artefacts, originating from the pleura that traverse the ultrasound screen, called B-lines. In a breathless patient, multiple (i.e. three or more in a single intercostal space, usually called 'chest zone'), diffuse (i.e. in more than one chest zone) and bilateral B-lines suggest a diagnosis of heart failure.<sup>37</sup> However, other conditions – for instance, adult respiratory distress syndrome or pulmonary fibrosis – may produce lung B-lines and distinguishing among them always requires a global assessment of the patient.<sup>38</sup>

Different protocols for the assessment of B-lines exist.<sup>39</sup> Overall, an increasing number of B-lines is associated with a faster respiratory rate, higher natriuretic peptides and a decreasing BMI; therefore, additional care must be taken when interpreting their number and distribution in obese patients.<sup>40,41</sup> Not surprisingly, in patients with either acute or chronic heart failure, an elevated number of B-lines is associated with a greater risk of cardiovascular events and there is accumulating evidence suggesting that it could be a therapeutic target.<sup>42,43</sup> The use of lung ultrasound might also facilitate identification of other frequent

complications of heart failure, such as pleural effusions, or concurrent lung diseases, such as pneumonia.<sup>44</sup>

### Renal Ultrasound

Heart failure is, in essence, a cardio-renal syndrome: assessment of blood flow within the kidney by ultrasound provides important clinical information. While a few studies suggest that impaired renal arterial flow correlates with higher natriuretic peptides and a poorer outcome, in recent years Doppler assessment of the interlobar veins has received particular attention to estimate central venous pressure (CVP) and intra-parenchymal congestion of the kidneys.<sup>45,46</sup> With a normal CVP, there is continuous renal venous flow during the whole cardiac cycle; as renal and intravascular congestion worsen, the flow pattern becomes discontinuous with two (systolic and diastolic; biphasic) or one (diastolic; monophasic) component in more severe cases, suggesting the need for urgent therapeutic action and a poor prognosis.<sup>47–49</sup> The use of a convex probe might facilitate the study of the kidney venous flow; however, visualisation of the interlobar veins can be difficult at times, particularly in those with severe renal dysfunction or who are unable to hold their breath for long periods to avoid diaphragmatic movements that interfere with correct renal evaluation by ultrasound.

### Other Cardiac Imaging Modalities

Coronary artery disease (CAD) is one of the most common causes of heart failure; its identification is important for risk stratification and – particularly in younger patients – therapeutic decisions.<sup>50</sup> Although the STICH trial did not demonstrate that coronary artery bypass graft surgery reduced all-cause mortality in patients with an LVEF  $\leq$ 35%, extended follow-up suggested a survival benefit, at least for younger patients.<sup>51</sup> Excluding CAD in patients with heart failure with a reduced LVEF might also be useful in selecting patients for an ICD.<sup>52</sup> Patients with CAD and well-controlled heart failure might also benefit from the addition of rivaroxaban 2.5 mg twice daily and statins.<sup>53,54</sup> In order to exclude important CAD, guidelines now recommend that CT coronary angiography may be considered.<sup>55</sup> For those who are symptomatic, either due to angina or to ventricular arrhythmias, invasive coronary angiography is currently recommended to assess severity and extent of CAD. CMR imaging can also be used to assess for the presence of significant CAD with stress perfusion imaging, or for evidence of scar from a prior MI with late gadolinium enhancement (LGE).<sup>56,57</sup>

CMR is also considered the gold standard test for assessing cardiac chamber volumes and, therefore, ejection fraction. CMR is angle-independent and not limited by factors that may have an impact on the quality of an echocardiographic exam such as a poor acoustic window or body habitus.<sup>58</sup> CMR has the unique ability among cardiac imaging techniques to provide detailed tissue characterisation, through the use of LGE and non-contrast tissue characterisation with cardiac mapping. Specifically, CMR can identify areas and patterns of myocardial fibrosis or scar, inflammation, fatty infiltration or iron overload, as well as quantifying extracellular volume. CMR's ability to characterise tissue can be particularly useful in determining the aetiology of heart failure, to improve risk stratification, or to guide individualised treatments in those with suspected sarcoidosis, amyloidosis or other infiltrative or inflammatory cardiomyopathies.<sup>56–59</sup> CMR shows that a surprisingly high number of people have myocardial scar consistent with a previous MI despite having no history of such an event. Patients with unrecognised (silent) MI have a similar prognosis to those with a recognised event, suggesting that the gadolinium-enhancement is not merely an artefact.<sup>60</sup> Of note (see below), patients with heart failure also have a high prevalence of unrecognised

(silent) cerebral infarctions. CMR does have limitations in terms of availability as the scanners are expensive; arrhythmia can reduce the accuracy of image quality and some implantable devices are not CMR conditional. For those with heart failure with cardiac or extracardiac red flags of transthyretin amyloidosis, <sup>99m</sup>Tc-DPD scintigraphy has a very high specificity and positive predictive diagnostic value for diagnosis.<sup>61</sup> An endomyocardial biopsy is usually reserved for selected cases, even in those with myocarditis presenting as heart failure.<sup>62</sup>

### Other Organs The Bowel

Heart failure may be associated with loss of appetite that – combined with hepatic and intestinal congestion – may lead to iron malabsorption, malnutrition and cachexia.<sup>63</sup> There is some evidence that patients with chronic heart failure have increased colonic wall thickness, perhaps reflecting oedema and reduced intestinal blood flow. This, in turn, may result in changes in the gut microbiota, triggering a systemic inflammatory response that may accelerate heart failure progression and death.<sup>64,65</sup> Bowel-wall thickness can be assessed by ultrasound and, when increased, is associated with greater congestion and poorer outcomes in patients with heart failure.<sup>63,66</sup>

### The Brain

The relationship between heart and brain dysfunction is complex. Many patients with heart failure report a variety of neurological symptoms, ranging from cognitive impairment and loss of attention to anxiety and depression.<sup>67,68</sup> Advanced age and hypoperfusion secondary to a reduced cardiac output or hypotension and atherosclerotic disease of the cerebral vessels might be key drivers of degenerative brain changes associated with heart failure.<sup>69</sup> However, micro- or macroembolic events, in the context of atherosclerotic disease in the carotids or an intracardiac thrombus, and/or the presence of other comorbidities common in heart failure such as hypertension, diabetes or AF, might also contribute to and accelerate brain damage. MRI scans suggest that patients with heart failure have several structural cerebral abnormalities, including white matter hyper-intensities, lacunar and cortical infarcts and cortical atrophy, even in the absence of a prior history of neurological symptoms or disease, similar to the high prevalence of silent MI noted above.<sup>70</sup> In

patients with heart failure, an inverse correlation has been reported between the density of cerebral grey matter in the hippocampus – a region implicated in development of cognitive dysfunction and memory loss – and N-terminal pro-B-type natriuretic peptide concentration; however, for those with less advanced heart failure, progression of hippocampal atrophy over time is minimal and perhaps not different from that expected due to ageing.<sup>71–73</sup>

### Skeletal Muscle

A loss of muscle mass, quality and/or strength – sarcopaenia – occurs in patients with advanced heart failure but, as with so many other aspects of heart failure, its presence and severity often go unrecognised until it is extreme and the patient is overtly cachectic.<sup>74</sup> Sarcopaenia, even when not clinically obvious, is associated with adverse outcomes. In clinical practice and research, several imaging methods are available to quantify muscle mass. MRI provides detailed information on muscle quantity and is a non-invasive gold standard tool for research in this setting but is not suitable for clinical use on a large scale due to high costs and limited access.<sup>75</sup> Dual-energy X-ray absorptiometry (DEXA) and bioelectrical impedance analysis (BIA) are widely available, affordable and easy to use in an ambulatory setting even by non-medical personnel.<sup>76</sup> Although there is a strong correlation between muscle mass measured with these two techniques (correlation coefficient >0.9), some studies suggest that BIA might produce higher readings for muscle mass compared with DEXA. In patients with heart failure, muscle mass measured with both techniques is only weakly associated with age or biomarkers of cardiac stress or inflammation but more closely related to other measures of body size, such as BMI or waist or hip circumference.<sup>77</sup>

### Conclusion

Modern imaging methods enable congestion – both haemodynamic/vascular and in tissues – to be identified and quantified objectively. Patients with cardiac dysfunction who have evidence of congestion on imaging are at increased risk of disease progression, heart failure decompensation and death, even if their symptoms and clinical signs appear adequately controlled. Whether early identification and treatment of congestion will improve outcomes is controversial, but accumulating evidence suggests that this might be the case. □

1. Pellicori P, Fitchett D, Kosiborod MN, et al. Use of diuretics and outcomes in patients with type 2 diabetes: findings from the EMPA-REG OUTCOME trial. *Eur J Heart Fail* 2021;23:1085–93. <https://doi.org/10.1002/ejhf.2220>; PMID: 34031968.
2. Bozkurt B, Coats AJ, Tsutsui H, et al. Universal definition and classification of heart failure: a report of the Heart Failure Society of America, Heart Failure Association of the European Society of Cardiology, Japanese Heart Failure Society and Writing Committee of the Universal Definition of Heart Failure. *J Card Fail* 2021;27:387–413. <https://doi.org/10.1016/j.cardfail.2021.01.022>; PMID: 33663906.
3. Cleland JGF, Pfeffer MA, Clark AL, et al. The struggle towards a universal definition of heart failure-how to proceed? *Eur Heart J* 2021;42:2331–43. <https://doi.org/10.1093/eurheartj/ehab082>; PMID: 33791787.
4. Taylor CJ, Ordóñez-Mena JM, Roalfe A, et al. Trends in survival after a diagnosis of heart failure in the United Kingdom 2000–2017: population based cohort study. *BMJ* 2019;364:l223. <https://doi.org/10.1136/bmj.l223>; PMID: 30760447.
5. Cleland JGF, Ferreira JP, Mariotti B, et al. The effect of spironolactone on cardiovascular function and markers of fibrosis in people at increased risk of developing heart failure: the Heart “OMics” in AGEing (HOMAGE) randomized clinical trial. *Eur Heart J* 2021;42:684–96. <https://doi.org/10.1093/eurheartj/ehaa758>; PMID: 33215209.
6. Beckett NS, Peters R, Fletcher AE, et al. Treatment of hypertension in patients 80 years of age or older. *N Engl J Med* 2008;358:1887–98. <https://doi.org/10.1056/NEJMoa0801369>; PMID: 18378519.
7. Pellicori P, Platz E, Dauw J, et al. Ultrasound imaging of congestion in heart failure: examinations beyond the heart. *Eur J Heart Fail* 2021;23:703–12. <https://doi.org/10.1002/ejhf.2032>; PMID: 33118672.
8. Marwick TH. The role of echocardiography in heart failure. *J Nucl Med* 2015;56(Suppl 4):31S–8S. <https://doi.org/10.2967/jnumed.114.150433>; PMID: 26033901.
9. Heidenreich PA, Bozkurt B, Aguilar D, et al. 2022 AHA/ACC/HFSA guideline for the management of heart failure: executive summary: a report of the American College of Cardiology/American Heart Association joint committee on clinical practice guidelines. *J Am Coll Cardiol* 2022;79:1757–80. <https://doi.org/10.1016/j.jacc.2021.12.011>; PMID: 35379504.
10. Kirkpatrick JN, Vannan MA, Narula J, Lang RM. Echocardiography in heart failure: applications, utility, and new horizons. *J Am Coll Cardiol* 2007;50:381–96. <https://doi.org/10.1016/j.jacc.2007.03.048>; PMID: 17662389.
11. Marwick TH. Ejection fraction pros and cons: JACC state-of-the-art review. *J Am Coll Cardiol* 2018;72:2360–79. <https://doi.org/10.1016/j.jacc.2018.08.2162>; PMID: 30384893.
12. Benamer N, Arous Y, Ben Abdallah N, Kraiem T. Comparison between 3D echocardiography and cardiac magnetic resonance imaging (CMRI) in the measurement of left ventricular volumes and ejection fraction. *Curr Med Imaging Rev* 2019;15:654–60. <https://doi.org/10.2174/157340516466180815115756>; PMID: 32008513.
13. Poon J, Leung JT, Leung DY. 3D echo in routine clinical practice - state of the art in 2019. *Heart Lung Circ* 2019;28:1400–10. <https://doi.org/10.1016/j.hlc.2019.04.003>; PMID: 31047786.
14. Sugimoto T, Dulgheru R, Bernard A, et al. Echocardiographic reference ranges for normal left ventricular 2D strain: results from the EACVI NORRE study. *Eur Heart J Cardiovasc Imaging* 2017;18:833–40. <https://doi.org/10.1093/ehjci/ehx140>; PMID: 28637227.
15. Nishikage T, Nakai H, Mor-Avi V, et al. Quantitative assessment of left ventricular volume and ejection fraction using two-dimensional speckle tracking echocardiography. *Eur J Echocardiogr* 2009;10:82–8. <https://doi.org/10.1093/ejehoccard/jen166>; PMID: 18490270.
16. Pellicori P, Kallivbacka-Bennett A, Khaleva O, et al. Global longitudinal strain in patients with suspected heart failure and a normal ejection fraction: does it improve diagnosis and risk stratification? *Int J Cardiovasc Imaging* 2014;30:69–79. <https://doi.org/10.1007/s10554-013-0310-y>; PMID: 24150723.
17. Cohen OC, Ismael A, Pawarova B, et al. Longitudinal strain is an independent predictor of survival and response to therapy in patients with systemic AL amyloidosis. *Eur Heart J* 2022;43:333–41. <https://doi.org/10.1093/eurheartj/ehab507>; PMID: 34472567.
18. Benjamin EJ, D’Agostino RB, Belanger AJ, et al. Left atrial size and the risk of stroke and death. The Framingham heart study. *Circulation* 1995;92:835–41. <https://doi.org/10.1161/01.cir.92.4.835>; PMID: 7641364.
19. Laukkanen JA, Kurl S, Eränen J, et al. Left atrium size and the risk of cardiovascular death in middle-aged men. *Arch Intern Med* 2005;165:1788–93. <https://doi.org/10.1001/archinte.165.15.1788>; PMID: 16087829.
20. Gupta S, Matulevicius SA, Ayers CR, et al. Left atrial

- structure and function and clinical outcomes in the general population. *Eur Heart J* 2013;34:278–85. <https://doi.org/10.1093/eurheartj/ehs188>; PMID: 22782941.
21. Rossi A, Temporelli PL, Quintana M, et al. Independent relationship of left atrial size and mortality in patients with heart failure: an individual patient meta-analysis of longitudinal data (MeRGE Heart Failure). *Eur J Heart Fail* 2009;11:929–36. <https://doi.org/10.1093/eurhf/hfp112>; PMID: 19789395.
  22. Pellicori P, Zhang J, Lukaschuk E, et al. Left atrial function measured by cardiac magnetic resonance imaging in patients with heart failure: clinical associations and prognostic value. *Eur Heart J* 2015;36:733–42. <https://doi.org/10.1093/eurheartj/ehu405>; PMID: 25336215.
  23. Inciardi RM, Claggett B, Minamisawa M, et al. Association of left atrial structure and function with heart failure in older adults. *J Am Coll Cardiol* 2022;79:1549–61. <https://doi.org/10.1016/j.jacc.2022.01.053>; PMID: 35450571.
  24. Reddy YNV, Obokata M, Egbe A, et al. Left atrial strain and compliance in the diagnostic evaluation of heart failure with preserved ejection fraction. *Eur J Heart Fail* 2019;21:891–900. <https://doi.org/10.1002/ejhf.1464>; PMID: 30919562.
  25. Ravassa S, López B, Ferreira JP, et al. Biomarker-based assessment of collagen cross-linking identifies patients at risk of heart failure more likely to benefit from spironolactone effects on left atrial remodelling. Insights from the HOMAGE clinical trial. *Eur J Heart Fail* 2022;24:321–31. <https://doi.org/10.1002/ejhf.2394>; PMID: 34841615.
  26. Pellicori P, Cleland JG, Zhang J, et al. Cardiac dysfunction, congestion and loop diuretics: their relationship to prognosis in heart failure. *Cardiovasc Drugs Ther* 2016;30:599–609. <https://doi.org/10.1007/s10557-016-6697-7>; PMID: 27819111.
  27. Iaconelli A, Pellicori P, Caiazzo E, et al. Implanted haemodynamic telemonitoring devices to guide management of heart failure: a review and meta-analysis of randomised trials. *Clin Res Cardiol* 2022;1–13. <https://doi.org/10.1007/s00392-022-02104-0>; PMID: 36241896.
  28. Etzeneini M, Gupta S, Li Y, et al. Estimation of right atrial pressure using a portable handheld ultrasound device. *Am J Med* 2022;135:1378–81. <https://doi.org/10.1016/j.amjmed.2022.05.018>; PMID: 35636478.
  29. Pellicori P, Shah P, Cuthbert J, et al. Prevalence, pattern and clinical relevance of ultrasound indices of congestion in outpatients with heart failure. *Eur J Heart Fail* 2019;21:904–16. <https://doi.org/10.1002/ejhf.1383>; PMID: 30666769.
  30. Cuthbert JJ, Pellicori P, Flockton R, et al. The prevalence and clinical associations of ultrasound measures of congestion in patients at risk of developing heart failure. *Eur J Heart Fail* 2021;23:1831–40. <https://doi.org/10.1002/ejhf.2353>; PMID: 34632680.
  31. Pellicori P, Carubelli V, Zhang J, et al. IVC diameter in patients with chronic heart failure: relationships and prognostic significance. *JACC Cardiovasc Imaging* 2013;6:16–28. <https://doi.org/10.1016/j.jcmg.2012.08.012>; PMID: 23328557.
  32. Goonewardena SN, Gemignani A, Ronan A, et al. Comparison of hand-carried ultrasound assessment of the inferior vena cava and N-terminal pro-brain natriuretic peptide for predicting readmission after hospitalization for acute decompensated heart failure. *JACC Cardiovasc Imaging* 2008;1:595–601. <https://doi.org/10.1016/j.jcmg.2008.06.005>; PMID: 19356487.
  33. Simon MA, Schnatz RG, Romeo JD, Pacella JJ. Bedside ultrasound assessment of jugular venous compliance as a potential point-of-care method to predict acute decompensated heart failure 30-day readmission. *J Am Heart Assoc* 2018;7:e008184. <https://doi.org/10.1161/JAHA.117.008184>; PMID: 30371245.
  34. Pellicori P, Kallvikbacka-Bennett A, Zhang J, et al. Revisiting a classical clinical sign: jugular venous ultrasound. *Int J Cardiol* 2014;170:364–70. <https://doi.org/10.1016/j.ijcard.2013.11.015>; PMID: 24315339.
  35. Pellicori P, Kallvikbacka-Bennett A, Dierckx R, et al. Prognostic significance of ultrasound-assessed jugular vein distensibility in heart failure. *Heart* 2015;101:1149–58. <https://doi.org/10.1136/heartjnl-2015-307558>; PMID: 26006717.
  36. Pellicori P, Clark AL, Kallvikbacka-Bennett A, et al. Non-invasive measurement of right atrial pressure by near-infrared spectroscopy: preliminary experience. A report from the SICA-HF study. *Eur J Heart Fail* 2017;19:883–92. <https://doi.org/10.1002/ejhf.825>; PMID: 28387033.
  37. Gargani L. Ultrasound of the lungs: more than a room with a view. *Heart Fail Clin* 2019;15:297–303. <https://doi.org/10.1016/j.hfc.2018.12.010>; PMID: 30832819.
  38. Gargani L. Lung ultrasound: a new tool for the cardiologist. *Cardiovasc Ultrasound* 2011;9:6. <https://doi.org/10.1186/1476-7120-9-6>; PMID: 21352576.
  39. Platz E, Jhund PS, Gierd N, et al. Expert consensus document: reporting checklist for quantification of pulmonary congestion by lung ultrasound in heart failure. *Eur J Heart Fail* 2019;21:844–51. <https://doi.org/10.1002/ejhf.1499>; PMID: 31218825.
  40. Palazzuoli A, Ruocco G, Beltrami M, et al. Combined use of lung ultrasound, B-type natriuretic peptide, and echocardiography for outcome prediction in patients with acute HFREF and HFpEF. *Clin Res Cardiol* 2018;107:586–96. <https://doi.org/10.1007/s00392-018-1221-7>; PMID: 29532155.
  41. Palazzuoli A, Ruocco G, Franci B, et al. Ultrasound indices of congestion in patients with acute heart failure according to body mass index. *Clin Res Cardiol* 2020;109:1423–33. <https://doi.org/10.1007/s00392-020-01642-9>; PMID: 32296972.
  42. Platz E, Merz AA, Jhund PS, et al. Dynamic changes and prognostic value of pulmonary congestion by lung ultrasound in acute and chronic heart failure: a systematic review. *Eur J Heart Fail* 2017;19:1154–63. <https://doi.org/10.1002/ejhf.839>; PMID: 28557302; PMCID: PMC5731779.
  43. Rastogi T, Bozec E, Pellicori P, et al. Prognostic value and therapeutic utility of lung ultrasound in acute and chronic heart failure: a meta-analysis. *JACC Cardiovasc Imaging* 2022;15:950–2. <https://doi.org/10.1016/j.jcmg.2021.11.024>; PMID: 35033496.
  44. Volpicelli G, Gargani L, Perlini S, et al. Lung ultrasound for the early diagnosis of COVID-19 pneumonia: an international multicenter study. *Intensive Care Med* 2021;47:444–54. <https://doi.org/10.1007/s00134-021-06373-7>; PMID: 33743018.
  45. Ciccone MM, Iacoviello M, Gesualdo L, et al. The renal arterial resistance index: a marker of renal function with an independent and incremental role in predicting heart failure progression. *Eur J Heart Fail* 2014;16:210–6. <https://doi.org/10.1002/ejhf.34>; PMID: 24664953.
  46. Tang WH, Kitai T. Intrarenal venous flow: a window into the congestive kidney failure phenotype of heart failure? *JACC Heart Fail* 2016;4:683–6. <https://doi.org/10.1016/j.jchf.2016.05.009>; PMID: 27395345.
  47. Pugliese NR, Pellicori P, Filidei F, et al. The incremental value of multi-organ assessment of congestion using ultrasound in outpatients with heart failure. *Eur Heart J Cardiovasc Imaging* 2023;jeac254. <https://doi.org/10.1093/ehjci/jeac254>; PMID: 36595324.
  48. Nijst P, Martens P, Dupont M, et al. Intrarenal flow alterations during transition from euvoemia to intravascular volume expansion in heart failure patients. *JACC Heart Fail* 2017;5:672–81. <https://doi.org/10.1016/j.jchf.2017.05.006>; PMID: 28711449.
  49. Iida N, Seo Y, Sai S, et al. Clinical implications of intrarenal hemodynamic evaluation by doppler ultrasonography in heart failure. *JACC Heart Fail* 2016;4:674–82. <https://doi.org/10.1016/j.jchf.2016.03.016>; PMID: 27198355.
  50. Rastogi T, Ho FK, Rossignol P, et al. Comparing and contrasting risk factors for heart failure in patients with and without history of myocardial infarction: data from HOMAGE and the UK biobank. *Eur J Heart Fail* 2022;24:976–84. <https://doi.org/10.1002/ejhf.2495>; PMID: 35365899.
  51. Velazquez EJ, Lee KL, Jones RH, et al. Coronary-artery bypass surgery in patients with ischemic cardiomyopathy. *N Engl J Med* 2016;374:1511–20. <https://doi.org/10.1056/NEJMoa1602001>; PMID: 27040723.
  52. Yafasova A, Butt JH, Elming MB, et al. Long-term follow-up of Danish (the Danish study) to assess the efficacy of ICDs in patients with nonischemic systolic heart failure on mortality). *Circulation* 2022;145:427–36. <https://doi.org/10.1161/CIRCULATIONAHA.121.056072>; PMID: 3882430.
  53. Branch KR, Probstfield JL, Eikelboom JW, et al. Rivaroxaban with or without aspirin in patients with heart failure and chronic coronary or peripheral artery disease. *Circulation* 2019;140:529–37. <https://doi.org/10.1161/CIRCULATIONAHA.119.039609>; PMID: 31163978.
  54. Cleland JG, Squire I, Ng L. Interpretation of amino-terminal pro-brain natriuretic peptide levels in the HPS and the CORONA study. *J Am Coll Cardiol* 2008;52:1104–5. <https://doi.org/10.1016/j.jacc.2008.04.070>; PMID: 18848145.
  55. McDonagh TA, Metra M, Adamo M, et al. 2021 ESC Guidelines for the diagnosis and treatment of acute and chronic heart failure: developed by the Task Force for the diagnosis and treatment of acute and chronic heart failure of the European Society of Cardiology (ESC). With the special contribution of the Heart Failure Association (HFA) of the ESC. *Eur J Heart Fail* 2022;24:4–131. <https://doi.org/10.1002/ejhf.2333>; PMID: 35083827.
  56. Karamitsos TD, Arvanitaki A, Karvounis H, et al. Myocardial tissue characterization and fibrosis by imaging. *JACC Cardiovasc Imaging* 2020;13:1221–34. <https://doi.org/10.1016/j.jcmg.2019.06.030>; PMID: 31542534.
  57. McDiarmid AK, Pellicori P, Cleland JG, Plein S. Taxonomy of segmental myocardial systolic dysfunction. *Eur Heart J* 2017;38:942–54. <https://doi.org/10.1093/eurheartj/ehw140>; PMID: 2747609.
  58. Peterzan MA, Rider OJ, Anderson LJ. The role of cardiovascular magnetic resonance imaging in heart failure. *Card Fail Rev* 2016;2:115–22. <https://doi.org/10.15420/cfr.2016.2.2.115>; PMID: 28785465.
  59. Menghoum N, Vos JL, Pouleur AC, et al. How to evaluate cardiomyopathies by cardiovascular magnetic resonance parametric mapping and late gadolinium enhancement. *Eur Heart J Cardiovasc Imaging* 2022;23:587–9. <https://doi.org/10.1093/ehjci/jeac051>; PMID: 35262680.
  60. Acharya T, Aspelund T, Jonasson TF, et al. Association of unrecognized myocardial infarction with long-term outcomes in community-dwelling older adults: the ICELAND MI study. *JAMA Cardiol* 2018;3:1101–6. <https://doi.org/10.1001/jamacardio.2018.3285>; PMID: 30304454.
  61. Gillmore JD, Maurer MS, Falk RH, et al. Nonbiopsy diagnosis of cardiac transthyretin amyloidosis. *Circulation* 2016;133:2404–12. <https://doi.org/10.1161/CIRCULATIONAHA.116.021612>; PMID: 27143678.
  62. Gräni C, Eichhorn C, Biere L, et al. Prognostic value of cardiac magnetic resonance tissue characterization in risk stratifying patients with suspected myocarditis. *J Am Coll Cardiol* 2017;70:1964–76. <https://doi.org/10.1016/j.jacc.2017.08.050>; PMID: 29025553.
  63. Valentova M, von Haehling S, Bauditz J, et al. Intestinal congestion and right ventricular dysfunction: a link with appetite loss, inflammation, and cachexia in chronic heart failure. *Eur Heart J* 2016;37:1684–91. <https://doi.org/10.1093/eurheartj/ehw008>; PMID: 26865478.
  64. Sandek A, Swidsinski A, Schroedl W, et al. Intestinal blood flow in patients with chronic heart failure: a link with bacterial growth, gastrointestinal symptoms, and cachexia. *J Am Coll Cardiol* 2014;64:1092–102. <https://doi.org/10.1016/j.jacc.2014.06.1179>; PMID: 25212642.
  65. Pellicori P, Zhang J, Cuthbert J, et al. High-sensitivity C-reactive protein in chronic heart failure: patient characteristics, phenotypes, and mode of death. *Cardiovasc Res* 2020;116:91–100. <https://doi.org/10.1093/cvr/cvz198>; PMID: 31350553.
  66. Ikeda Y, Ishii S, Maemura K, et al. Association between intestinal oedema and oral loop diuretic resistance in hospitalized patients with acute heart failure. *ESC Heart Fail* 2021;8:4067–76. <https://doi.org/10.1002/ehf2.13525>; PMID: 34323025.
  67. Cannon JA, Moffitt P, Perez-Moreno AC, et al. Cognitive impairment and heart failure: a systematic review and meta-analysis. *J Card Fail* 2017;23:464–75. <https://doi.org/10.1016/j.cardfail.2017.04.007>; PMID: 28433667.
  68. Sokoreli I, Pauws SC, Steyerberg EW, et al. Prognostic value of psychosocial factors for first and recurrent hospitalizations and mortality in heart failure patients: insights from the OPERA-HF study. *Eur J Heart Fail* 2018;20:689–96. <https://doi.org/10.1002/ejhf.1112>; PMID: 29314447.
  69. Sherwi N, Wong K, Zhang J, et al. The prevalence of extra-cranial carotid artery disease in chronic heart failure. *Cardiol Angiol Int J* 2014;3:17–26. <https://doi.org/10.9734/CA/2015/10584>.
  70. Vogels RL, van der Flier WM, van Harten B, et al. Brain magnetic resonance imaging abnormalities in patients with heart failure. *Eur J Heart Fail* 2007;9:1003–9. <https://doi.org/10.1016/j.ejheart.2007.07.006>; PMID: 17719270.
  71. Mueller K, Thiel F, Beutner F, et al. Brain damage with heart failure: cardiac biomarker alterations and gray matter decline. *Circ Res* 2020;126:750–64. <https://doi.org/10.1161/CIRCRESAHA.119.315813>; PMID: 31969053.
  72. Woo MA, Ogren JA, Abouzeid CM, et al. Regional hippocampal damage in heart failure. *Eur J Heart Fail* 2015;17:494–500. <https://doi.org/10.1002/ejhf.241>; PMID: 25704495.
  73. Frey A, Homola GA, Henneges C, et al. Temporal changes in total and hippocampal brain volume and cognitive function in patients with chronic heart failure—the COGNITION. MATTERS-HF cohort study. *Eur Heart J* 2021;42:1569–78. <https://doi.org/10.1093/eurheartj/ehab003>; PMID: 33496311.
  74. Zhang Y, Zhang J, Ni W, et al. Sarcopenia in heart failure: a systematic review and meta-analysis. *ESC Heart Fail* 2021;8:1007–17. <https://doi.org/10.1002/ehf2.13255>; PMID: 33576177.
  75. Kumar A, Ansari BA, Kim J, et al. Axial muscle size as a strong predictor of death in subjects with and without heart failure. *J Am Heart Assoc* 2019;8:e010554. <https://doi.org/10.1161/JAHA.118.010554>; PMID: 30755074.
  76. Gonzalez MC, Heymsfield SB. Bioelectrical impedance analysis for diagnosing sarcopenia and cachexia: what are we really estimating? *J Cachexia Sarcopenia Muscle* 2017;8:187–9. <https://doi.org/10.1002/jcsm.12159>; PMID: 28145079.
  77. Shah P, Abel AAI, Boyalla V, et al. A comparison of non-invasive methods of measuring body composition in patients with heart failure: a report from SICA-HF. *ESC Heart Fail* 2021;8:3929–34. <https://doi.org/10.1002/ehf2.13402>; PMID: 34216106.