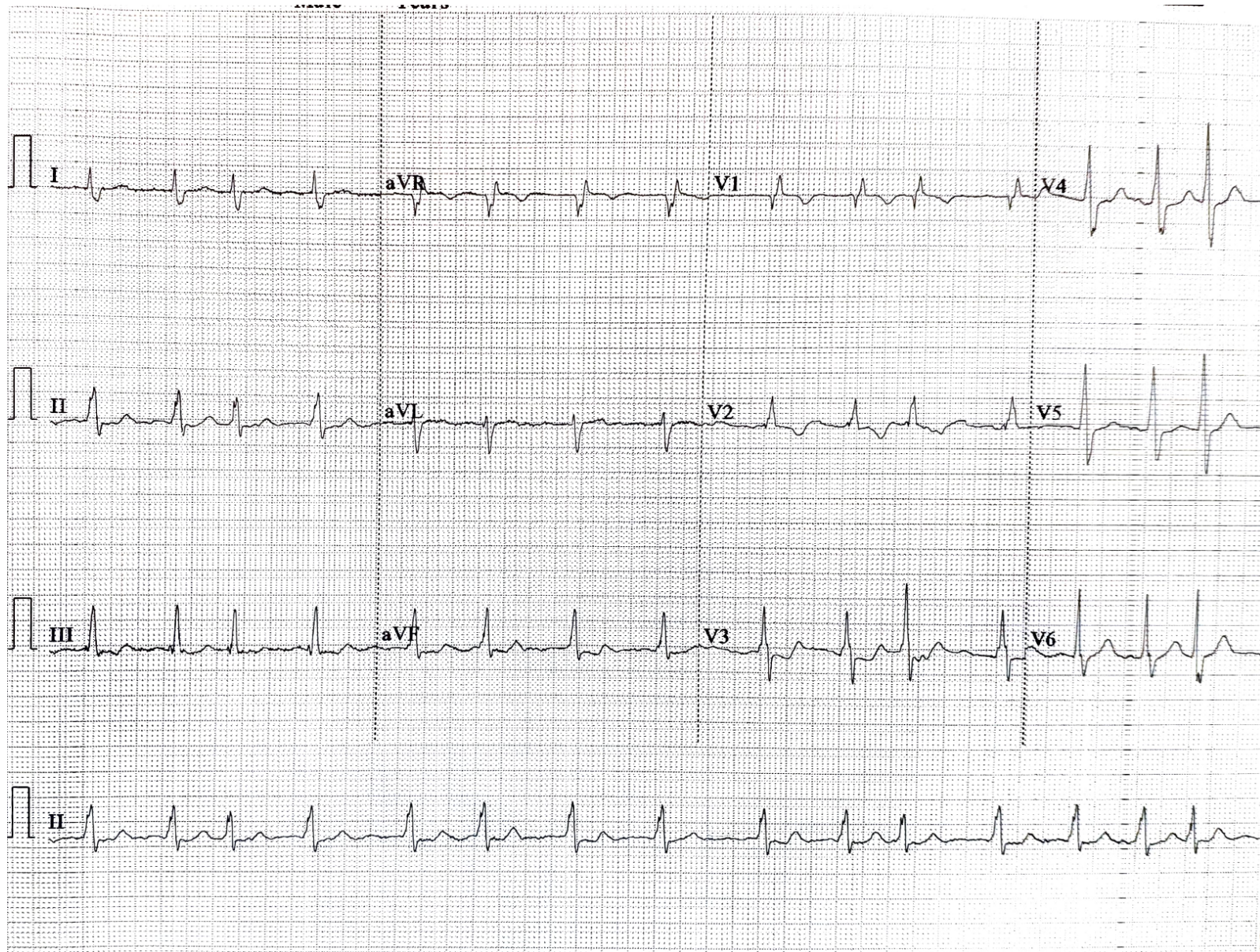


Supplementary Figure 1



Electrocardiogram. The initial electrocardiogram revealed absence of P waves, with an irregularly irregular rhythm supportive of atrial fibrillation. In addition, there was evidence of right axis deviation, prominent R waves in lead V1-2 and prominent S waves in leads V3–V6.