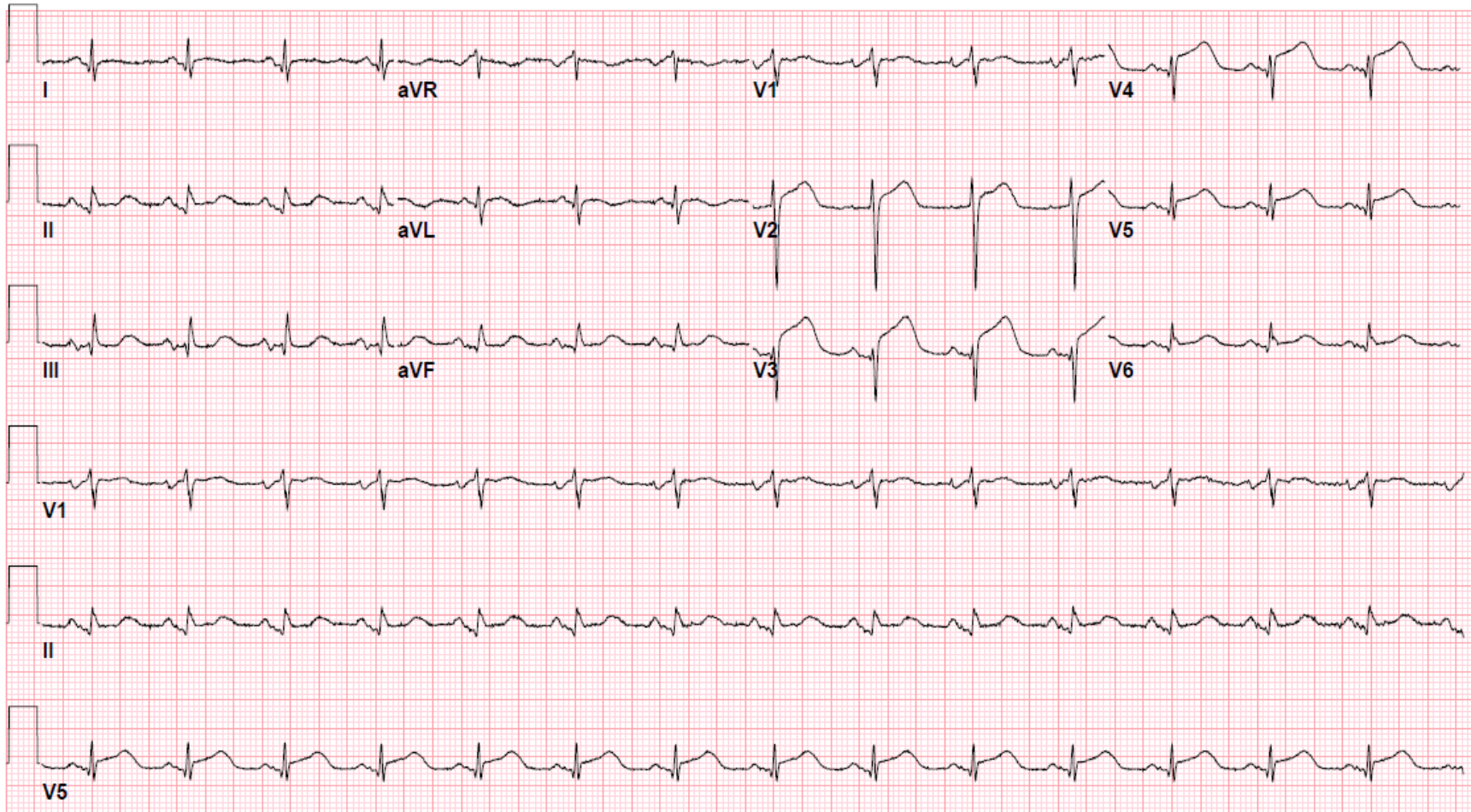


Supplementary Figure 1: Initial 12-lead-electrocardiogram with ST segment elevation (STE) in leads V2-V4



Supplementary Figure 2: 2D echocardiograms.

(Left) 2D echocardiogram showing apical aneurysm and a ventricular septal defect in inferior septum (blue arrow)

(Right) Color Doppler flow demonstrating left-to-right flow (red arrow)

