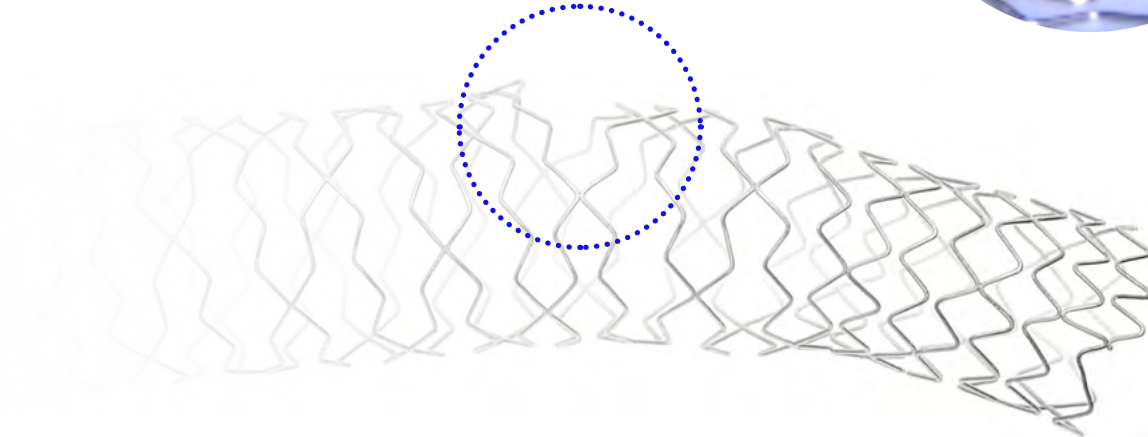



## 1.2 TAP technique



# T and small protrusion (TAP) introduction

**TAP- stenting was developed and reported by Burzotta et al in 2007,**

with the aim of improving the T-stenting technique to ensure full ostial coverage, where bifurcation geometry prevents perfect alignment of stents and to provide a strategy to facilitate final KBI.

## Definition

The T and small protrusion (TAP) technique is a modification of provisional T-stenting aimed at optimizing implantation of a second stent in bifurcated coronary lesions treated using the provisional pathway.

The stent from the SB is intentionally positioned with a small (1-2 mm) protrusion in the MV, to fully cover the ostium area and is deployed simultaneously with a balloon positioned in the MV.

> <https://eurointervention.pconline.com/article/treatment-of-coronary-bifurcation-lesions-part-ii-implanting-two-stents-the-16th-expert-consensus-document-of-the-european-bifurcation-club>

> <https://pubmed.ncbi.nlm.nih.gov/25983182/>

# T and small protusion (TAP) in practice


## A second stent may be needed when:

- › Suboptimal SB result determined via angiography
- › Clinical or functional signs of ischemia
- › Suboptimal SB result determined by additional imaging
  - Impaired TIMI flow
  - Dissection type B or worse
  - Residual stenosis >80%
  - Threatened SB closure

## The TAP technique has several strengths, including:<sup>1</sup>

- › Compatibility with 6 Fr guiding catheters
- › Full coverage of the side branch ostium
- › Facilitates final kissing balloon inflation

- › <https://eurointervention.pconline.com/article/treatment-of-coronary-bifurcation-lesions-part-ii-implanting-two-stents-the-16th-expert-consensus-document-of-the-european-bifurcation-club>
- › <https://pubmed.ncbi.nlm.nih.gov/25983182/>



# TAP step-by-step

A continuation from provisional

